



PATIENT

Cody Gaudreau

SPECIES

Canine

BREED

Maltese

SEX

Male Neutered

AGE

9 years

WEIGHT

10.44lbs

INTERPRETED BY

Maggie Machen
Lamy, DVM
DACVIM (Cardiology)

IMAGING PERFORMED BY

Pamela Harrigan,
RDCS

HOSPITAL NAME

Mass Veterinary Services

REFERRING VET

Dr. Masloski

INVOICE

22318

DATE

12/7/21

PRESENTING CLINICAL SIGNS

History: History chronic valvular disease, advanced. Prior echo 6/5/21: severe MR, severe LAE/LVE (measurements not available). CV/RESP: NSR, grade IV/VI murmur with PMI left apical area radiating to right, PSS, lung fields clear. BP: 160mmHg x 5.

-Current medications:) Pimobendan/vetmedin 5mg 1/4 tab twice a day 2) Enalapril 2.5mg 1 tab am with 1/2 tab pm 3) Lasix/furosemide 12.5mg 1/2 tab in am 4) Spironolactone 25mg 1/4 tab pm 5) Gabapentin 50mg/5mls 1 ml for vet visit *No sedation for study.

ECHOCARDIOGRAM FINDINGS

2D, m-mode, color flow and Doppler imaging is available.

Left ventricle: Significant LV dilation with hyperdynamic myocardial function.

Left atrium: The left atrium is markedly dilated.

Mitral valve: Diffuse thickening of mitral valve leaflets with significant prolapse into the left atrial lumen. Severe eccentric mitral regurgitation with a normal velocity.

Aortic valve/Aorta: The aortic valve is normal in morphology and mobility. Normal aortic outflow velocity; laminar flow. No aortic insufficiency.

Right ventricle: Mild RV dilation.

Right atrium: Mild right atrial dilation.

Tricuspid valve: The tricuspid valve appears thickened, with mild tricuspid regurgitation. Mildly elevated velocity consistent with mild pulmonary hypertension.

Pulmonic valve/Pulmonary artery: The pulmonic valve is normal in morphology and mobility. The MPA appears mildly dilated. Normal pulmonic outflow velocities with laminar flow. No PI.

Pericardium/other: No pericardial or pleural effusion noted. No obvious cardiac masses.

Heart rhythm: ECG reveals a sinus rhythm with an average HR of 220bpm.

2-Dimensional Measurements

Ao diam (cm)	1.1
LA diam (cm)	3.5
LA:Ao (Swe)	3.0
IVS thickness (cm)	0.54
LVID diastole (cm)	3.2
PW thickness (cm)	0.54
LVID systole (cm)	1.3
FS (%)	59

Doppler Measurements

PV Vmax (m/s)	1.2
AoV Vmax (m/s)	1.4
MR Vmax (m/s)	5.8
TR Vmax (m/s)	3.0
TR PG (mmHg)	36

INTERPRETATION OF THE FINDINGS

Chronic degenerative valve disease persists with severe mitral and mild tricuspid regurgitation. Marked left atrial enlargement indicates the risk for spontaneous congestive heart failure is elevated. Mild pulmonary hypertension is noted, which is likely secondary to chronic LA pressure elevation. No additional issues are identified.

Even without clinical signs given the severity of disease seen here, I would increase both Lasix and Spironolactone to q12h dosing. No additional medication changes are warranted in the absence of clinical signs.

The average survival time of canine patients with active pulmonary edema is 8-9 months on medications, however they generally are able to maintain a good quality of life for that period. Patient will always be at risk for recurrent CHF, development of arrhythmias/LA tear, syncope and/or sudden death in the future.



PATIENT

Cody Gaudreau

SPECIES

Canine

BREED

Maltese

SEX

Male Neutered

AGE

9 years

WEIGHT

10.44lbs

INTERPRETED BY

Maggie Machen Lamy, DVM
DACVIM (Cardiology)

IMAGING PERFORMED BY

Pamela Harrigan, RDCS

HOSPITAL NAME

Mass Veterinary Services

REFERRING VET

Dr. Masloski

INVOICE

22318

DATE

12/7/21

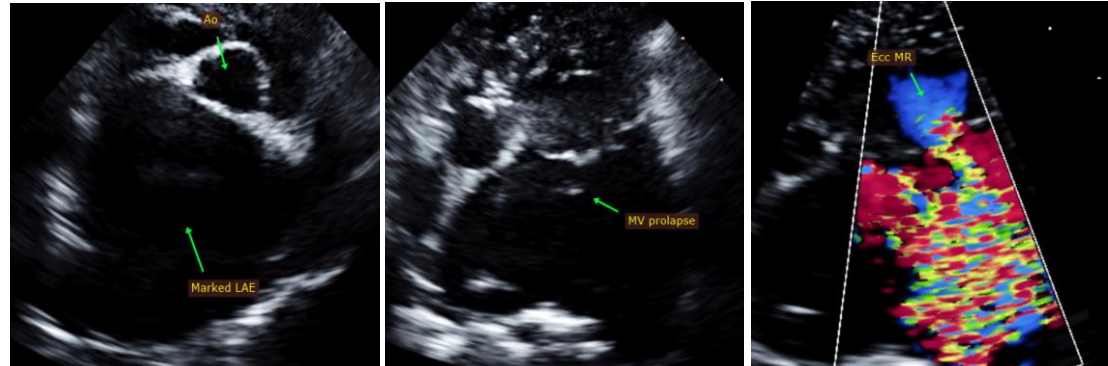
RECOMMENDATIONS

- Increase Lasix to 6.25mg PO q12h.
- Increase Spironolactone 6.25mg PO q 12h.
- Continue Pimobendan and Enalapril as prescribed.
- Cough suppression to improve QOL can also be considered (hydrocodone, 0.2-0.4mg/kg up to q4-6h PRN) for any residual mechanical cough in the face of normal sleeping respiratory rates.
- Monitor for development of a cough, labored breathing, exercise intolerance or collapse episodes.
- Monitoring of sleeping respiratory rates will be paramount to screen for congestive heart failure at home.
- Elective anesthesia is not advised.
- Omega fatty acid supplementation and mild salt restriction may be of some long-term benefit.

PLAN

- Monitor renal values and BP in 1-2 weeks, then every 3-4 months lifelong.
- Recommend conservative monitoring with a recheck echocardiogram in 6 months, sooner if any development of clinical signs.

IMAGES



The information and recommendations provided are based on the images presented by the referring veterinarian. No evaluation can be communicated regarding pathology that was not visible in the image/video clips provided.

Thank you for this referral. This report was generated using transcription software, and minor dictation errors may be present. If the clinical or image interpretation does not parallel your findings or if I can be of any further assistance, please contact me.

Maggie Machen Lamy, DVM
Diplomate of the American College of Veterinary Internal Medicine (Cardiology)
info@sonopath.com

Echocardiogram performed by: Pamela Harrigan, RDCS
Pet Animal Ultrasound Service (4paus.com)